

# Upper Diagnostic Triangle

<sup>1</sup>Milling Tania, <sup>2</sup>RK Vijayakumar, <sup>3</sup>JM Jeyaraj

## ABSTRACT

**Aims and objectives:** To test the validity of the concept of 'dentoalveolar compensation' by using a geometric model called the upper diagnostic triangle.

**Methods:** A triangle is constructed using SN plane, NA plane, and long axis of upper incisor to the SN plane. The triangle is mathematically analyzed to evaluate the concept of passive dental offset and dentoalveolar compensation. The mathematical model is applied to a clinical case and the analysis is presented.

**Conclusion:** Upper diagnostic triangle serves as a useful mathematical model and emphasizes on passive dental offset as sequelae to skeletal deviation and indicates the extent of presurgical orthodontics.

**Keywords:** Geometric offset, Dentoalveolar compensation, Diagnostic triangle, Cephalometrics, Sella, NA.

**How to cite this article:** Tania M, Vijayakumar RK, Jeyaraj JM. Upper Diagnostic Triangle. J Ind Orthod Soc 2013;47(4):280-285.

## INTRODUCTION

The evaluation of the position of upper incisor<sup>1,2</sup> is a key stone to effective diagnosis, treatment planning of an orthodontic problem and for successful outcome of the treatment. The spatial location of upper incisor in three-dimensions of space and its inclination and angulation has profound impact and is the most important single feature on the static esthetics<sup>3</sup> and dynamic charm<sup>4-7</sup> in the act of smile. With such high stakes on the importance of upper incisor, it would not be a futile exercise for orthodontists to seek a simple and effective diagnostic means to describe upper incisor and how it relates itself to underlying skeletal base. A vital component of such evaluation is the sagittal position of the upper incisor as seen in the lateral 2D cephalogram. This evaluation when synthesized with other clinical parameters and diagnostic aids is sure to hone the diagnostic skills of the orthodontist and help in arriving at a simple and effective diagnosis.

Earlier, the importance of positioning the lower incisor followed by the positioning of upper incisors relative to the lower incisors was emphasized to achieve optimum esthetics and stability.<sup>8,9</sup> This minimal emphasis on the position of upper incisor was due to the fact that neither surgical correction nor

functional appliance therapy was popular as today.<sup>10</sup> Furthermore, it was also suggested that the maxillary incisors might be the best teeth to use for esthetic prognosis since they determined both the upper and lower lip postures.<sup>2</sup> The concept of planned incisor position<sup>10</sup> with the idea of visualizing an ideal position of the upper incisor at the start of treatment and subsequently fitting all the other teeth around this ideal position gained popularity later. With the advent of various improved orthodontic, surgical and other combined treatment modalities and with esthetics taking the priority in some selective cases, emphasis has shifted in such cases more toward the upper incisors as a benchmark reference.

Upper diagnostic triangle (UDT) is presented as a pedagogic mathematical model to describe and diagnose upper dentofacial structure. Simplicity, ease of understanding and applicability were the foundations for proposing such a model.

The aim was to study if a geometrical correlation between skeletal and dental parameters can be inferred from such a mathematical model and also to test the validity of the concept of dentoalveolar compensation<sup>11-16</sup> in skeletal deviation cases.

## METHODS

A mathematical model to diagnose the upper dentofacial structure is presented in the form of a triangle (UDT, Fig. 1). The three sides are:

1. SN plane
2. NA plane
3. Long axis of upper incisor to the SN plane.

The three corners of the triangle are:

1. S point
2. N point
3. Point of intersection of NA line and long axis of the most proclined upper incisor.

<sup>1</sup>Senior Lecturer, <sup>2,3</sup>Professor

<sup>1</sup>Department of Orthodontics, Rajas Dental College, Chennai, Tamil Nadu, India

<sup>2</sup>Department of Orthodontics, Sri Ramakrishna Dental College, Chennai Tamil Nadu, India

<sup>3</sup>Private Practice, Department of Orthodontics, Tamil Nadu, India

**Corresponding Author:** Milling Tania, Senior Lecturer, Department of Orthodontics, Rajas Dental College, Chennai, Tamil Nadu, India e-mail: taniadhas@yahoo.com

Received on: 4/11/12

Accepted after Revision: 5/1/13

The inner angles of the triangle are:

|                               |                   |
|-------------------------------|-------------------|
| SNA                           | 82° <sup>17</sup> |
| Upper incisor to NA           | 22° <sup>17</sup> |
| Upper incisor to SN (derived) | 76°               |

The values are drawn from standard norms.

In a normal skeleton with optimum inclination of the upper incisor, the inner angles are SNA 82°, upper incisor to NA plane 22°, upper incisor to SN plane 76° (Fig. 1). (The sum of the inner angles of a triangle should be 180°). The triangle here is constructed with the median values of established norms expressing normal skeletal and dental relation. The proposed method being in the form of a triangle, certain theorems governing the mathematical model of a triangle can be used to interpret the upper dentofacial structure.

**PROPOSED THEOREMS FOR GEOMETRIC INTERPRATATION OF UPPER DIAGNOSTIC TRIANGLE**

**Theorem 1 (Fig. 1)**

SNA, UI to NA, UI to SN are normal  
 $SNA + (UI\ to\ NA) + (UI\ to\ SN) = 82^\circ + 22^\circ + 76^\circ = 180^\circ$   
 and  
 $SNA + (UI\ to\ NA) = 104^\circ,$   
 $(UI\ to\ NA) + (UI\ to\ SN) = 98^\circ$   
 $(UI\ to\ SN) + SNA = 158^\circ$   
 Where UI is upper incisor

**Interpretation: Normal Skeletal and Dental Relation**

A perfect skeletal and dental relation. The ultimate goal of treatment planning in any type of case will be to restore this normal geometry of upper diagnostic triangle.

**Theorem 2 (Fig. 2)**

SNA and UI to NA are not normal  
 UI to SN normal  
 But Sum of SNA + (UI to NA) = 104°  
 Where there is variation in SNA and that variation is perfectly offset by changes in (UI to NA).

**Interpretation: Skeletal Deviations**

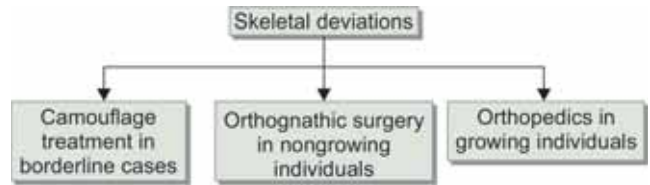
1. A variation in SNA which means a prognathism or retrognathism of maxilla has a passive reflection in UI to NA. This change in UI to NA plane is due to the change in the position of point A and not due to the change in the inclination of the long axis of the upper incisor. This secondary or passive change of UI to NA plane owing to a change in the SNA is called a passive geometric offset. This 'passive geometric offset' should not be misinterpreted as 'dentoalveolar compensation'.
2. Active correction of SNA by orthognathic surgical or orthopedic means will bring about a passive normalization of UI to NA.

**Clinical Application**

1. In cases falling within the confines of this theorem, the likely mode of treatment is orthopedic in growing or

orthognathic surgery in nongrowing individuals and camouflage treatment in borderline cases.

**Treatment Options**



**Theorem 3 (Fig. 3)**

SNA normal  
 UI to NA and UI to SN not normal  
 $Sum\ of\ (UI\ to\ NA) + (UI\ to\ SN) = 98^\circ,$   
 Where variation in (UI to NA) is perfectly offset at (UI to SN).

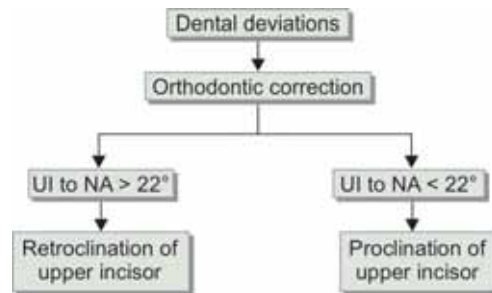
**Interpretation: Dental Deviations**

1. A variation in (UI to NA) which means a proclination or retroclination has a passive reflection in (UI to SN). This secondary or passive change is a geometric offset.
2. Active correction of UI to NA purely by orthodontic means will bring about a passive normalization of UI to SN.

**Clinical Application**

1. In cases falling within the confines of this theorem, orthodontic correction is the likely mode of treatment.

**Treatment Options**



**Theorem 4 (Fig. 4)**

SNA, UI to NA, UI to SN are not normal  
 $SNA + (UI\ to\ NA)$  is not equal to 104° and  
 $(UI\ to\ NA) + (UI\ to\ SN)$  is not equal to 98°

**Interpretation: Skeletal with Accompanying Dental Deviations**

- A. The amount of deviation of the sum of SNA + (UI to NA) from normalcy (104°) gives an indication of the degree of change in the inclination of the incisor.  
 If  $SNA + (UI\ to\ NA) < 104^\circ$  (Fig. 4)  
 $104^\circ - [SNA + (UI\ to\ NA)] =$  amount of retroclination of incisor

If  $SNA + (UI\ to\ NA) > 104^\circ$   
 $[SNA + (UI\ to\ NA)] - 104^\circ =$  amount of proclination of incisor

**Note:** A dental deviation can be either positive or negative. A positive dental deviation can be rightly called dentoalveolar compensation which is actually nature’s attempt to camouflage the underlying skeletal problem by a change in the dental inclination beyond the geometric offset to facilitate a proper functional anterior interocclusal relation in the sagittal plane (Overjet).

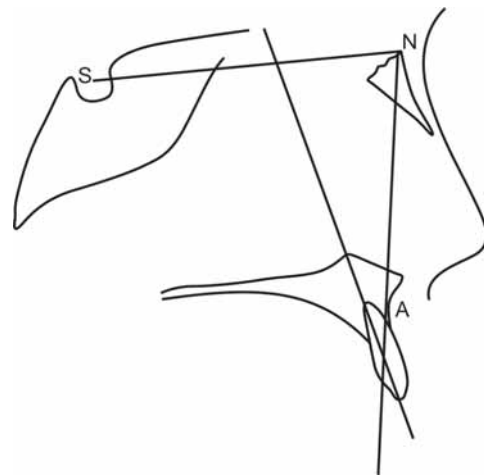
- A. Deviation in the inclination of the incisor which can exaggerate the underlying skeletal problem can be called a negative dentoalveolar deviation.
- B. The amount of deviation of the sum of (UI to NA) + (UI to SN) from normalcy ( $98^\circ$ ) denotes a change in the sagittal position of the maxilla.

If  $(UI\ to\ NA) + (UI\ to\ SN) < 98^\circ$  (Fig . 4)  
 $98^\circ - [(UI\ to\ NA) + (UI\ to\ SN)] =$  amount of prognathism of maxilla  
 If  $(UI\ to\ NA) + (UI\ to\ SN) > 98^\circ$   
 $[(UI\ to\ NA) + (UI\ to\ SN)] - 98^\circ =$  amount of retrognathism of maxilla.

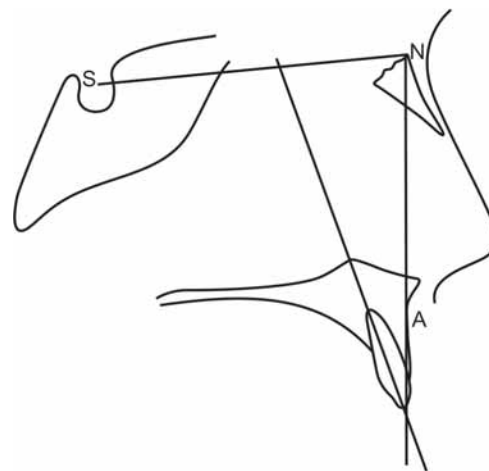
**Clinical Application**

1. In cases falling within the confines of this theorem, initially orthopedic treatment to correct the skeletal deviation is done followed by orthodontic treatment to correct the dental problem in a growing individual. Whereas in a non-growing individual initially orthodontic treatment to correct the dental deviation is done followed by surgery to correct the skeletal problem.

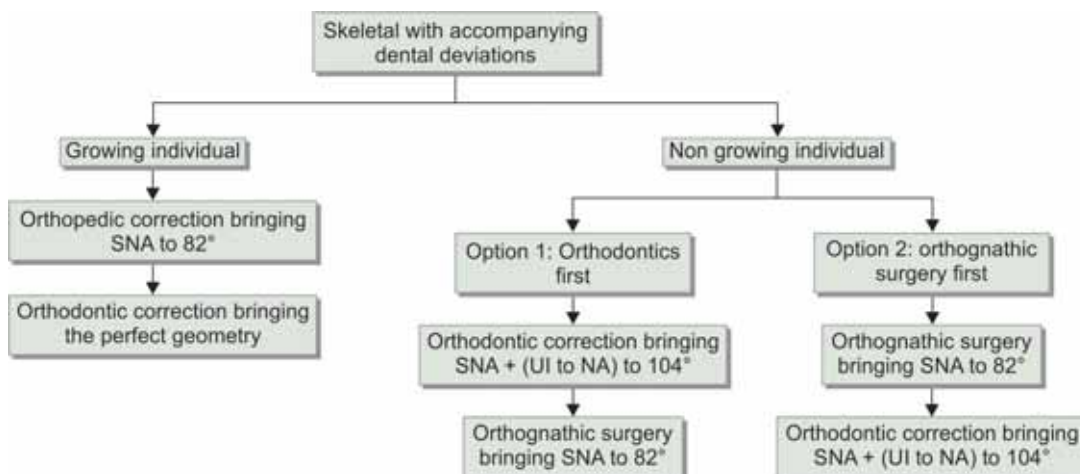
**Treatment Options**



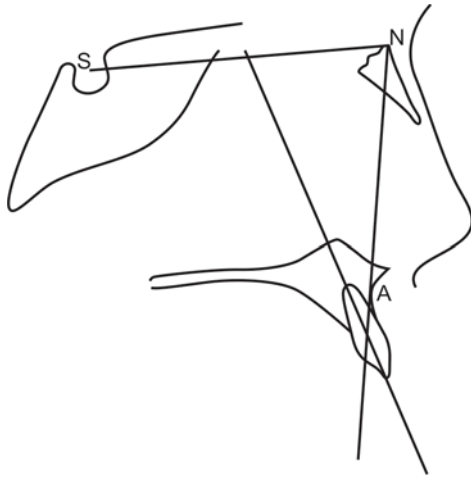
**Fig. 1:** Normal skeletal and dental relation  
 SNA 82°  
 Upper incisor to NA 22°  
 Upper incisor to SN 76°



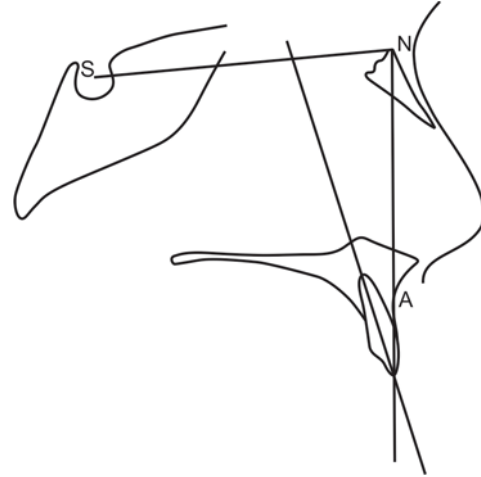
**Fig. 2:** Maxillary prognathism  
 SNA 85° (n + 3°)  
 Upper incisor to NA 19° (n + geometric compensation of -3°)  
 Upper incisor to SN 76° (unaltered)  
 n Denotes normal value



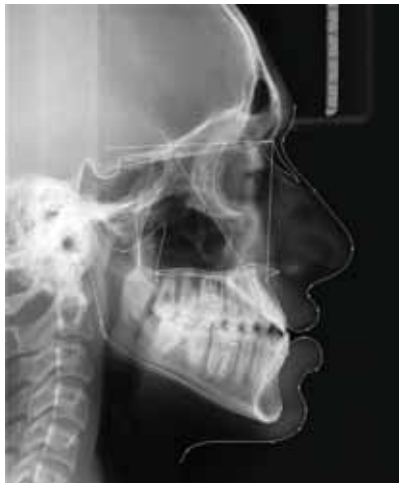Note: When achieving SNA to 82° becomes impractical, camouflage treatment to an acceptable esthetic range can be an option



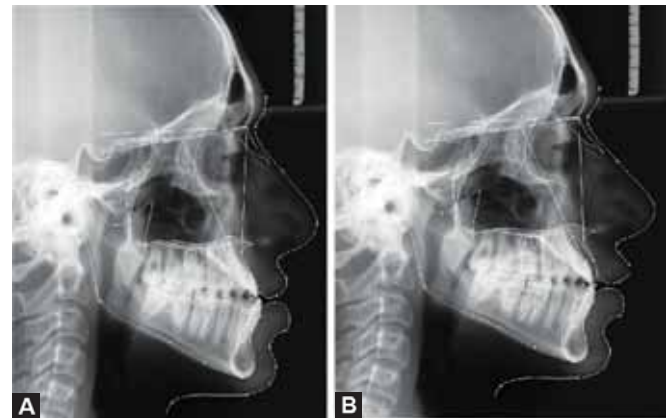
**Fig. 3:** Proclination of upper incisor on a Class I skeletal base  
 SNA 82°  
 Upper incisor to NA 27° (n + dental proclination of 5°)  
 Upper incisor to SN 71° (n - 5) altered due to dental proclination  
 n Denotes normal value



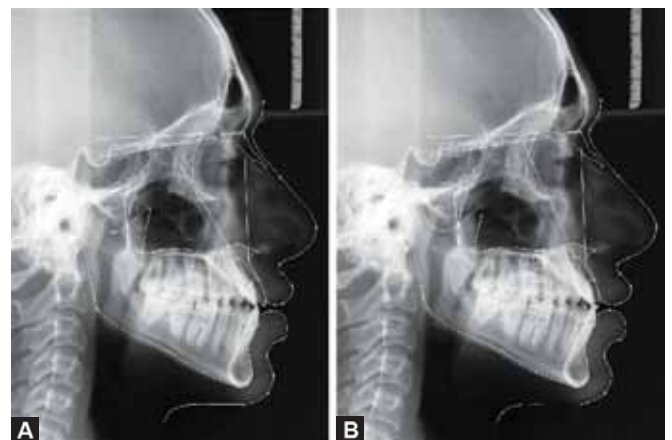
**Fig. 4:** Maxillary prognathism with upper incisor retroclination  
 SNA 85° (n + 3°)  
 Upper incisor to NA 16° (n + geometric compensation of -3° + dental compensation of -3°)  
 Upper incisor to SN 79° (n + 3°) altered due to dental compensation  
 n Normal value



**Fig. 5:** Illustration case  
 SNA 78° (n - 4°)  
 Upper incisor to NA 34° (n + geometric compensation of 4° + dental proclination of 8°)  
 Upper incisor to SN 68° (n - 8°) altered due to dental proclination  
 n Denotes normal value



**Figs 6A and B:** (A) Option 1: Step 1: Presurgical orthodontics: Retraction of UI to NA to 26° (when UI to SN passively gets restored to 76°), (B) Option 1: Step 2: Maxillary advancement procedure to correct retrognathism by 4° which restores SNA at 82° (when UI to NA gets passively restored to 22°)



**Figs 7A and B:** (A) Option 2: Step 1: Maxillary advancement procedure to correct retrognathism by 4° restoring SNA at 82° (when UI to NA gets passively restored to 30°), (B) Option 2: Step 2: Orthodontic correction: Retraction of UI to NA from 30° to 22° (when the UI to SN passively gets restored to 76°)

**DISCUSSION**

In the present era, with the objective of esthetics taking the importance in diagnosing and treatment planning in selected cases, there seems to be an obvious need for a simple diagnostic tool which bases its diagnosis and treatment planning on a parameter which has got an esthetic and functional contribution to the dentofacial complex. It is realized that the keystone to the diagnosis and treatment planning as far as the upper facial structure is concerned is the upper central incisor. Thus, the upper diagnostic triangle bases its diagnosis around upper central incisor which supports the upper and lower lip and which has also been credited as one of the main determinants of esthetics.<sup>2</sup> The upper diagnostic triangle



relating the position of upper central incisor to the upper face and cranium, rightly echoes the increasing pitch of esthetic component in diagnosing and planning the treatment in the recent trends. The main objective of proposing such a diagnostic triangle is to strike a balance between simplicity and efficacy in aiding toward the diagnosis and treatment plan. The proposed upper diagnostic triangle (UDT) is drawn on a triangular geometric model and the three sides of the triangle are the long axis of the upper central incisor, NA plane and SN plane.

The long axis of the upper central incisor, forming one of the sides of the triangle with specific values between the other planes better postures its relation to the face and cranium. Even minor positional changes are sensed by the angular variations which is said to be more accurate than linear variation because of its independency of radiographic magnification.<sup>18</sup> A change in the value can either depict a true change in the inclination of the upper incisor or a secondary change owing to the change in the orientation of the reference planes it is related to, i.e. NA and SN plane. This passive alteration occurring secondary to the change in NA or SN plane can be rightly called the 'Geometric offset'. The knowledge of differentiating geometric offset and a true dental deviation becomes very important in planning the treatment especially in surgical cases. In sagittal maxillary skeletal problem with a geometric compensation of the incisor, mere surgical correction of the skeletal problem without any presurgical orthodontics will restore the normal geometry of the triangle. Whereas in a case with maxillary skeletal problem with a dental deviation, presurgical orthodontics to correct the deviated dental inclination should precede the surgical procedure to restore the normal geometry of the triangle. Thus, this diagnostic tool with the knowledge of the theorems proposed gives a clue of the amount of dental deviation or geometric offset achieved, thereby helping in treatment planning.

The other side of the triangle being formed by the NA plane highlights the position of the upper face in relation to the cranium and the upper incisor. SN plane<sup>19</sup> forming one of the sides of the triangle is selected as the reference plane due to the advantages it possesses, i.e. easy identifiability, easy reproducibility, early stabilization of the structures associated with it.

The theorems proposed depict the variations in the geometry of the upper diagnostic triangle in different cases eliciting a skeletal, dental or a combination of skeletal and dental problems.

### Theorem 1: Normal Skeletal and Dental Relation (Fig. 1)

Theorem 1 explains the normal geometry of the upper diagnostic triangle in cases which exhibit normal skeletal and dental relation.

### Theorem 2: Skeletal Deviations (Fig. 2)

Theorem 2 explains the variations in the geometry of the upper diagnostic triangle in cases which exhibit sagittal skeletal deviations of the maxilla. In maxillary prognathism with normal dental inclination (Fig. 2), SNA increases, upper incisor to NA decreases as a geometric compensation due to the positional variation of A point in spite of the inclination of upper incisor unchanged, whereas upper incisor to SN plane remains unchanged reflecting the unchanged position of the incisor. Similarly, maxillary retrognathism with normal dental inclination manifests as decrease in SNA with increased upper incisor to NA as a geometric compensation and upper incisor to SN plane remaining unchanged highlighting the unchanged position of the incisor. The variation in SNA is perfectly offset by the changes in UI to NA plane to bring out a sum of  $104^\circ$ . Thus, a pure skeletal problem is sensed by a change in SNA, a change in upper incisor to NA as a perfect geometric compensation and an unchanged upper incisor to SN plane. In such cases active correction of SNA by orthognathic surgical means in nongrowing or orthopedic means in growing individuals will bring about a passive normalization of upper incisor to NA.

### Theorem 3: Dental Deviations (Fig. 3)

Theorem 3 explains the variations in the geometry of the triangle in cases which exhibit dental deviations. In a case with proclination of incisor on a normal skeletal base (Fig. 4), SNA remains normal, upper incisor to NA increases, upper incisor to SN decreases, whereas in retroclination of incisor on a Class I, skeletal base, SNA remains normal, upper incisor to NA decreases, upper incisor to SN increases. The variation in upper incisor to NA is perfectly offset at upper incisor to SN to bring out a perfect sum of  $98^\circ$ . Thus, a pure dental problem can be sensed by a change in the angulation of upper incisor to NA plane and upper incisor to SN plane with SNA remaining normal. In such cases active correction of upper incisor to NA plane by orthodontic means will bring about a passive normalization of upper incisor to SN plane.

### Theorem 4: Skeletal with Accompanying Dental Deviations (Fig. 4)

Theorem 4 explains those cases with a combination of skeletal and dental variations where in SNA, (UI to NA), (UI to SN) are not normal,  $SNA + (UI\ to\ NA)$  not equal to  $104^\circ$ ,  $(UI\ to\ NA) + (UI\ to\ SN)$  not equal to  $98^\circ$ . When  $SNA + (UI\ to\ NA)$  is not equal to  $104^\circ$ , the amount of deviation from normalcy denotes the degree of change in the inclination of the incisor. When  $(UI\ to\ NA) + (UI\ to\ SN)$  is not equal to  $98^\circ$ , the amount of deviation from normal value denotes the degree of change in the sagittal position of the maxilla. In such cases in an adult patient, presurgical orthodontics to correct the deviated dental

inclination should precede the surgical procedure to restore the normal geometry of the triangle. In a growing individual, orthopedic treatment to correct the skeletal deviation should precede the orthodontic treatment for the achievement of the normal geometry.

## Application of UDT in Diagnosis and Treatment Plan

### Illustrative Case (Fig. 5)

#### Diagnosis

|          |     |
|----------|-----|
| SNA      | 78° |
| UI to NA | 34° |
| UI to SN | 68° |

This is a case of 4° maxillary retrognathism, where according to theorem 2 the UI to NA should ideally be at 26° (including the geometric offset). But in addition to this, the patient presents with a dental deviation of 8°.

#### Treatment Options

##### Orthodontics first (Figs 6A and B)

*Step 1:* Presurgical orthodontics: Retraction of UI to NA to 26° (when the UI to SN passively gets restored to 76°).

*Step 2:* Maxillary advancement procedure to correct retrognathism by 4° which restores SNA at 82° (When UI to NA gets passively restored to 22°).

*Surgery first (Figs 7A and B):* This option can be considered where the visualized occlusal objective will not interfere with the surgical correction, when the treatment plan is considered in total along with the lower facial skeleton and occlusion.

*Step 1:* Maxillary advancement procedure to correct retrognathism by 4° restoring SNA at 82° (When UI to NA gets passively restored to 30°).

*Step 2:* Orthodontic correction: Retraction of UI to NA from 30° to 22° (when the UI to SN passively gets restored to 76°).

## CONCLUSION

1. Relating upper incisor to the underlying skeletal base is critical for treatment planning in both orthodontic and orthognathic surgical cases where esthetics plays a key role.
2. UDT as first of its series, analyses only sagittal deviation.
3. The mathematical model explains the 'passive dental deviation', which at times has erroneously been called 'dentoalveolar compensation', does not require presurgical orthodontics.
4. The proposed model proves that the changes in dental angulation can be due to a passive geometric offset in

relation to the underlying skeletal base or a true dental deviation or a combination of both.

5. The various combinations of conditions are explained mathematically in the form of four theorems. Thus, the upper diagnostic triangle when used in combination with other clinical parameters and diagnostic aids helps the clinician in diagnosis and treatment planning.

## REFERENCES

1. Riedel RA. The relation of maxillary structures to cranium in malocclusion and in normal occlusion. *Angle Orthod* 1952;22:142-145.
2. Holdaway RA. A soft-tissue cephalometric analysis and its use in orthodontic treatment planning. Part I. *Am J Orthod* 1983;84:1-28.
3. Hulsey CM. An esthetic evaluation of lip-teeth relationships present in the smile. *Am J Orthod* 1970;57:132-144.
4. Sarver DM. The importance of incisor positioning in the esthetic smile: the smile arc. *Am J Orthod Dentofacial Orthop* 2001;120:98-111.
5. Dickens S, Sarver DM, Proffit WR. The dynamics of the maxillary incisor and the upper lip: a cross-sectional study of resting and smile hard tissue characteristics. *World J Orthod* 2002;3:313-320.
6. Sarver DM, Ackerman MB. Dynamic smile visualization and quantification: Part 1. Evolution of the concept and dynamic records for smile capture. *Am J Orthod Dentofacial Orthop* 2003;124:4-12.
7. Sarver DM, Ackerman MB. Dynamic smile visualization and quantification. Part 2. Smile analysis and treatment strategies. *Am J Orthod Dentofacial Orthop* 2003;124:116-127.
8. Tweed, Charles H. The Frankfurt-mandibular-incisor angle (FMIA) in orthodontic diagnosis, treatment planning and prognosis. *Angle Orthod* 1954;24:121-169.
9. Margolis HI. Axial inclination of mandibular incisors. *Am J Orthod Oral Surg* 1943;29:571-594.
10. McLaughlin R, Bennett J, Trevisi H. Systemized orthodontic treatment mechanics. Mosby Company, 1st ed. 2001;p162.
11. Donovan RW. Recent research for diagnosis. *Am J Orthod* 1954;60:591-609.
12. Solow B. The dentoalveolar compensatory mechanism: Background and clinical implications. *Br J Orthod* 1980;7:145-161.
13. Ishikawa H, Nakamura S, Iwasaki H, Kitazawa S, Tsukada H, Sato Y. Dentoalveolar compensation related to variations in sagittal jaw relationships. *Angle Orthod* 1999;69:534-538.
14. Ishikawa H, Nakamura S, Iwasaki H, Kitazawa S, Tsukada H, Chu S. Dentoalveolar compensation in negative overjet cases. *Angle Orthod* 2000;70:145-148.
15. Ceylan I, Yavuz I, Arslan F. The effects of overjet on dentoalveolar compensation. *Eur J Orthod* 2003;25:325-330.
16. Baydas B, Yavuz I, Dagsuyu IM, Bolukbasi B, Ceylan I. An investigation of maxillary and mandibular morphology in different overjet groups. *Aust Orthod J* 2004;20:11-18.
17. Steiner CC. The use of cephalometrics as an aid to planning and assessing orthodontic treatment. *Am J Orthod* 1960;46:721-735.
18. Baumrind S, Frantz RC. The reliability of head film Part 2. Conventional angular and linear measures. *Am J Orthod* 1971;60:505-517.
19. Wei SHY. The variability of roentgenographic cephalometric lines of reference. *Angle Orthod* 1968;38:74-78.